

William Parker, MD, FACS, RPhS
Vascular Surgeon, Hamilton Vein Center, San Antonio, TX

Improvement in both symptoms and appearance with Varithena

Patient History

- A 68-year-old male requested a consultation after symptoms interfered with his work and daily activities. His symptoms included bilateral torturous varicose veins that were tender to the touch, ankle swelling, skin discoloration, leg pain, and restless legs. His job as a roofer required him to be standing and sitting for prolonged periods of time leading to worsening of symptoms.
- Previous intervention included two years of compression therapy that had unsuccessfully treated his symptoms and previous ablation procedures on both proximal GSVs.

Patient Assessment: CEAP CLASS 4A

- Duplex ultrasound revealed bilateral reflux in distal GSVs and tributaries. Skin changes were also present making the patient CEAP class 4.
- Right leg vein diameters were 3.0mm in the distal GSV and ranged from 3.1mm to 3.7mm in the calf tributaries.
- Left leg vein diameters were 4.7mm in the distal GSV, 5.3mm in the thigh tributaries, 4.4mm in the knee tributaries, and 4.2mm in the calf tributaries.

Treatment

- It was determined that two sessions were needed, separated by one week, with the left leg undergoing treatment first.

- In both procedures, the treated leg was mapped with ultrasound and access points were marked. A 25g butterfly needle was used for access, then the leg was elevated to 45 degrees.
- The left leg was treated with 15cc of Varithena in two access sites (one proximal GSV site near the medial knee and one distal GSV site in the medial calf).
- The right leg was treated with 13cc of Varithena in two access sites (one proximal GSV site near the lateral knee and one distal GSV site in the posterior calf).
- After each procedure, the treated veins were observed for spasm, then compression wrapping and 20-30mmHg compression stockings were applied. The total treatment volume was 28cc of Varithena.

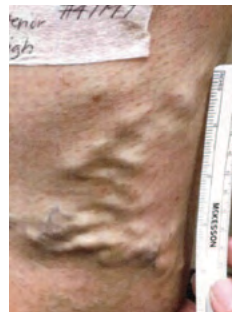

Figure 1.
Left Thigh Pre-treatment

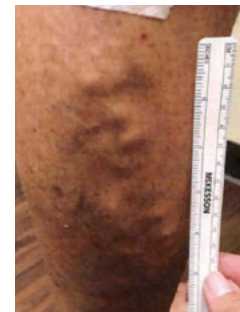

Figure 2.
Left Calf Pre-treatment

Results

- The patient followed up in clinic one month post procedure. He had significant symptom improvement and was able to return to work. He said he was able to go up and down ladders without any pain and stated his legs now feel wonderful.
- Follow-up exams did not show any signs of superficial reflux or DVTs and treated veins were confirmed to be closed.

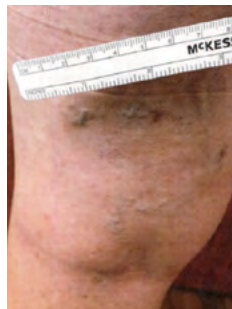

Figure 3.
Left thigh one-month
post-Varithena treatment

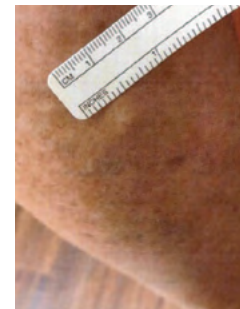


Figure 4.
Left Calf one-month
post-Varithena treatment

Conclusion

- Due to this patient's extensive bilateral disease, it was necessary to stagger his treatments over two visits. The procedure was tolerated well with no complications. Post-treatment instructions were followed and the patient stated he was very pleased with the results of the procedure.
- The patient will follow-up in clinic for treatment of varicose tributaries if they become symptomatic.

"Without Varithena I would not have been able to treat these tortuous veins."

William Parker, MD, FACS
Board Certified:
General Vascular Surgery





Varithena (polidocanol injectable foam)

INDICATIONS Varithena (polidocanol injectable foam) is indicated for the treatment of incompetent great saphenous veins, accessory saphenous veins and visible varicosities of the great saphenous vein (GSV) system above and below the knee. Varithena improves the symptoms of superficial venous incompetence and the appearance of visible varicosities.

IMPORTANT SAFETY INFORMATION The use of Varithena is contraindicated in patients with known allergy to polidocanol and those with acute thromboembolic disease. Severe allergic reactions have been reported following administration of liquid polidocanol, including anaphylactic reactions, some of them fatal. Observe patients for at least 10 minutes following injection and be prepared to treat anaphylaxis appropriately. Intra-arterial injection or extravasation of polidocanol can cause severe necrosis, ischemia or gangrene. Patients with underlying arterial disease may be at increased risk for tissue ischemia. If intra-arterial injection of polidocanol occurs, consult a vascular surgeon immediately. Varithena can cause venous thrombosis. Follow administration instructions closely and monitor for signs of venous thrombosis after treatment. Patients with reduced mobility, history of deep vein thrombosis or pulmonary embolism, or recent (within 3 months) major surgery, prolonged hospitalization, or pregnancy are at increased risk for developing thrombosis. The most common adverse events observed were pain/discomfort in extremity, retained coagulum, injection site hematoma or pain, common femoral vein thrombus extension, superficial thrombophlebitis, and deep vein thrombosis. Physicians administering Varithena must be experienced with venous procedures, possess a detailed working knowledge of the use of the duplex ultrasound in venous disease and be trained in the administration of Varithena.

For Full Prescribing Information visit Varithena.com

Varithena™ is a registered trademark of Boston Scientific. All other trademarks are property of their respective owners.

PI-1263705-AA

**Boston
Scientific**
Advancing science for life™

Peripheral Interventions

300 Boston Scientific Way
Marlborough, MA 01752-1234
www.bostonscientific.com

*To order product or for more information
contact customer service at 1.888.272.1001.*

© 2023 Boston Scientific Corporation
or its affiliates. All rights reserved.

PI-796106-AA